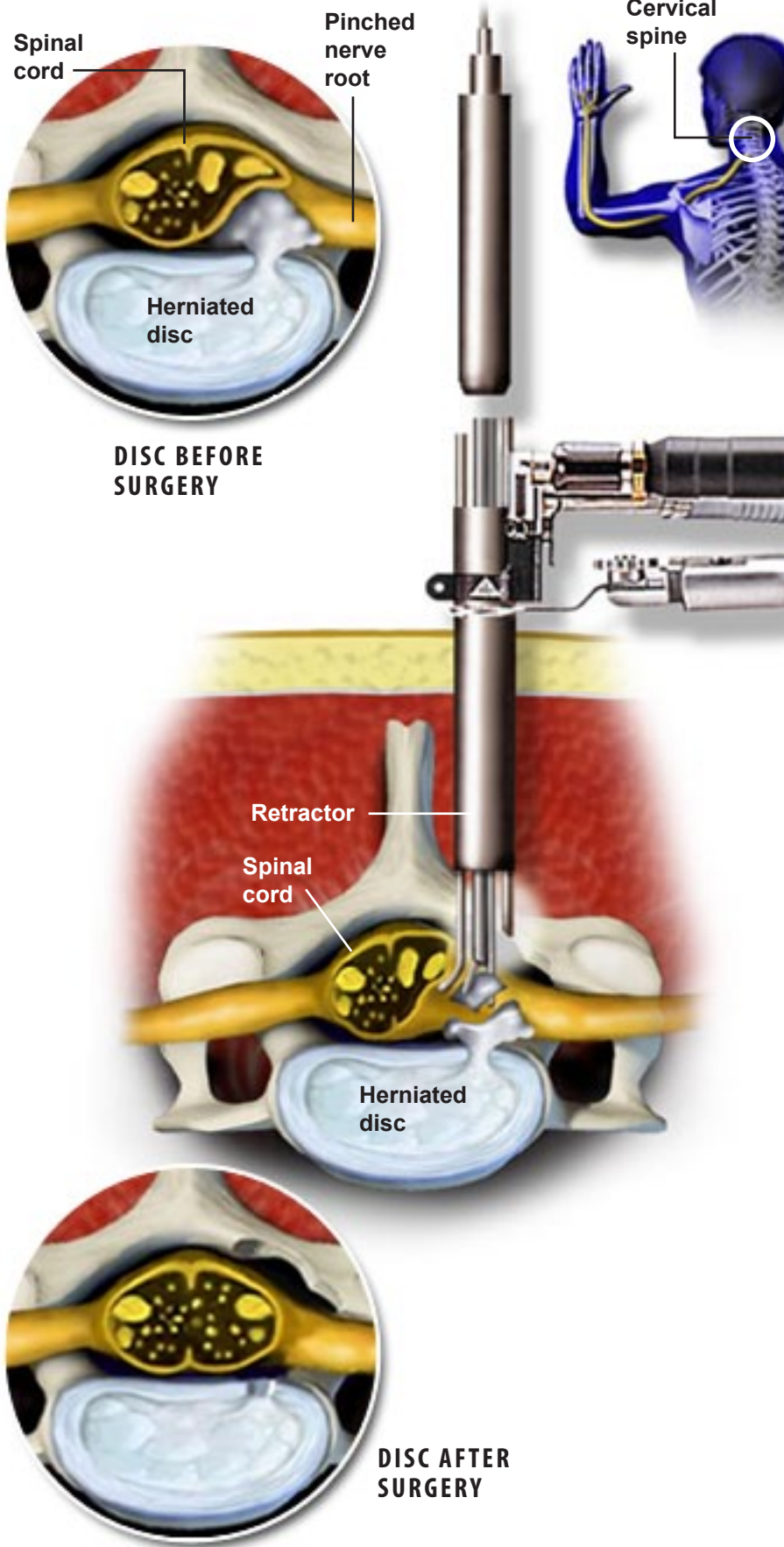


Micro Endoscopic Posterior Cervical Discectomy



DISC BEFORE SURGERY

DISC AFTER SURGERY

Overview

This surgery removes bone and/or portions of a herniated or diseased disc to relieve neck and radiating arm pain caused by parts of the disc pressing on nerve roots.

Guide Wire Inserted

Through a small incision, a guide wire is inserted to locate the affected disc level. The surgeon uses a special type of x-ray machine called a fluoroscope to ensure that the route to the herniated disc is made in the correct location.

Tubes Inserted

A series of dilation tubes are passed over the guide wire, pushing apart the tissue and creating an opening to the vertebrae. The guide wire then is removed.

Retractor Positioned

The tubular retractor, through which the surgery will be performed, slides over the dilating tubes. It is positioned on the bone surface. All the dilating tubes are then removed.

Instruments Inserted

A surgical light and small camera or microscope are placed through the tube to allow the surgeon to view the disc. The surgeon uses surgical instruments to clear away bone and soft tissue, accessing the spinal canal.

Nerve Exposed

A drill may be used to clear away bone, exposing the pinched nerve root and the herniated disc below it.

Nerve Inspected

A small instrument is passed through the retractor tube and used to check the freedom of the nerve.

Damaged Disc Removed

The surgeon removes the herniated portion of the disc and clears the area, creating room for the nerve to move back to its normal position.

End of Procedure

The tubular retractor is removed, allowing the tissue to close. The surface wound is covered with a small bandage.